

## Vitamin D Aggravates the Metabolic Side Effects of Olanzapine in Female Rats

Ghada S Mahmoud<sup>1,2</sup>, Dalia G. Mostafa<sup>3</sup>

<sup>1</sup>Assistant Professor, Departments of Medical Physiology, Faculty of Medicine, Assiut University, Assiut, Egypt,

<sup>2</sup>Visitor Assistant Professor, Departments of Basic Medical Science, Faculty of Physical Therapy, Deraya University, El-Minya, Egypt.

<sup>3</sup>Lecturer, Departments of Medical Physiology, Faculty of Medicine, Assiut University, Assiut, Egypt.

### Abstract:

**Objective:** Atypical antipsychotics represented a major advance in the treatment of schizophrenia and minimizing the extrapyramidal side effects. However, the use of atypical antipsychotics have been linked to weight gain, hyperglycemia, metabolic syndrome and risk of liver affection. Previous studies proposed that vitamin D deficiency may contribute to the development of insulin resistance, metabolic syndrome and more recently fatty liver. The goal of this study was to investigate the role of vitamin D in protection against the metabolic and hepatic side effects of olanzapine.

**Methods:** Eighteen female albino rats received treatment by gavage for 5 weeks and divided into; C group: received (0.5ml/day) of normal saline and olive oil (0.2ml) twice weekly, (O) group: received olanzapine (2mg/kg/day) and olive oil (0.2ml) twice weekly, and (O+D) group: received olanzapine (2mg/kg/day) and vitamin D3 (vit.D3) (125mcg/ Kg) orally by gavage twice weekly. Plasma levels of lipid panel, liver enzymes, glucose, insulin, Interleukin-6 (IL-6), Interleukin-10 (IL-10), and Tumor necrosis-alpha (TNF-α) were determined. H & E staining of liver tissue were performed to assess the effects of vit.D3 treatment on olanzapine-induced histopathology.

**Results:** Co-administration of vit.D3 caused significant elevation of IL-6, IL-10, HDL/LDL and mild improvement of liver histopathology. However, it caused further elevation of triglycerides (TGs), total cholesterol (TC), very low density lipoproteins (VLDL), TNF-α, liver enzymes, plasma, bilirubin, and impaired glucose tolerance. Insignificant difference in weight gain and abdominal fat was found.

**Conclusion:** These results suggest that olanzapine-induced disturbed lipid profile and hepatic steatosis is independent of weight gain. Moreover, this study provides an evidence for adverse effects of vitamin D supplementation especially in patients treated with olanzapine.

**Keywords:** Antipsychotic, Fatty liver disease, Metabolic syndrome, Olanzapine, Vitamin D, Non-alcoholic steatohepatitis, Liver function.

### I. Introduction

Antipsychotics are group of drugs used to treat not only psychotic disorders such as schizophrenia and bipolar disorders but also non-psychotic disorders [1]. Diseases such as dementia of old age, autism, obsessive compulsory disorder, resistant depression, manifestations associated with developmental disorders in children are treated with antipsychotics [1], [2], [3].

In contrast with typical antipsychotic drugs, atypical antipsychotic drugs (AAD) are effective against both negative symptoms such as depression and positive symptoms as hallucinations and delusions as well as they improve cognition [4]. Olanzapine has been proved to be one of the most effective drug compared to other AAD of its group [5]. Moreover, Milka et al suggested that DNA methylation may play a role in the therapeutic efficacy of olanzapine [6]. Unfortunately, the use AAD in general and olanzapine in particular is associated with glucose intolerance, insulin resistance, weight gain, increased triglycerides, and hepatic disorders that may lead to discontinuation of the drug [5]. Therefore, the administration of safe dietary supplement that could protect against olanzapine side effects is of utmost importance.

Previous studies demonstrated that vitamin D deficiency aggravates metabolic disorders in nonalcoholic steatohepatitis induced by clozapine in rats [7]. One study showed that vitamin D supplementation attenuated the hepatic malfunction and cognitive defect induced by high fructose diet in rat model of metabolic syndrome [8]. The purpose of this study is to examine the effect of vitamin D supplementation in protection against the inflammatory liver disease and glucose intolerance induced by olanzapine. We measured blood glucose, insulin, parameters of lipid profile, liver enzymes, total protein, albumin, total bilirubin, direct bilirubin and inflammatory cytokines after coadministration of olanzapine and vit.D3 compared to olanzapine alone for 5 weeks.

## **II. Material and Methods**

### **II.1 Drugs and chemicals:**

Olanzapine (Eli Lilly and Co., Indianapolis, IN). Each tab 5 mg mashed and dissolved in 5ml normal saline and given at dose (2 mg/ kg / day) by gavage for 5 weeks [9]. Devarol S Memphis Co. for Pharm. & Chem. Ind. Each 2 ml contains cholecalciferol (Vit.D3) 5 mg (equivalent to 200000 I.U.) dissolved in 48 ml olive oil equivalent to (4000 IU in 1 ml). We gave 125mcg/ Kg (5 IU/ gm or 0.125µl/ gm) by gavage twice weekly for 5 weeks [10].

### **II.2 Animal model**

Eighteen young adult female Albino rats were subjected for 1 week of normal temperature and light/dark cycle before experimentation. They were allowed free access to food and water (Ad Libitum). All experiments were carried out in strict accordance with the applicable national and international guidelines. The protocol was approved by the Local Experimental Ethical Committee at Deanship of Scientific Research of Assiut University, Assiut. All surgery was done under ether anesthesia, and all efforts were made to minimize suffering.

### **II.3 Experimental design of research**

Weight and waist circumference were measured at the beginning and end of the experiment for all rats. Waist circumference was measured by using plastic tape according to the method done by Gerbaix et al. [11] Rats were divided into three groups sex animals in each group; (C) group: served as control rat received 0.5 ml/day of normal saline and 0.2 ml of olive oil twice weekly. (O) group: included rats which received olanzapine 2mg/ kg/ day and olive oil (0.2ml). (O+D) group: received olanzapine (2mg/kg/day) and vit.D3 (125mcg/ kg). All animals received treatment by gavage for five weeks.

After 12 hours fasting, rats in all groups were anaesthetized with ether. Blood samples were collected from all rats into heparinized tubes by retro orbital puncture before scarification. Plasma was separated by centrifugation at 3000 rpm for 10 minutes and stored at -80°C until analysis. Abdominal incision was done, sternum cut in the middle, rats infused with cold physiologic saline followed by 10% formalin through cardiac puncture and liver was excised from all animals at the time of sacrifice, washed with ice-cold physiologic saline solution for further histological processing.

### **II.4 Biochemical parameters**

Alanine aminotransferase (ALT) and Aspartate aminotransferase (AST) were estimated in plasma by using diagnostic kit ALT (EC 2.6.1.2) liquiUV test and AST (EC 2.6.1.1) liquiUV test; both ALT and AST ordered from Human Gesellschaft für Biochemica und Diagnostica (mbH, Wiesbaden, Germany); Alkaline phosphatase (ALP: AL F080 CH) purchased from (chema Diagnostica 60030 Monsano (AN)- ITALY-EU) and Gamma glutamyl transaminase (GGT: REF 99 35 61) purchased from (Quimica Clinica Aplicada A7 km 1081 p.o. Box 20 – E43870 Amposta, Spain) by using (Gamma-GT LIQUIDA: Szasz modified method).

The reagents for the determination of Total Cholesterol (TC: CHOD POD Method ref 99 52 20) purchased from (Quimica Clinica Aplicada A7 km 1081 p.o. Box 20 – E43870 Amposta, Spain); Triglycerides (TGs: TR F100 CH); High density lipoproteins (HDL-c Direct FL: HD F080 CH); Albumin (BC 0100 CH); Total protein (TP 0100 CH); (TGs, HDL-c, total protein and albumin were purchased from chema Diagnostica 60030 Monsano (AN)- ITALY-EU); Very low density lipoproteins (VLDL) is calculated using the formula of Tremblay et al (VLDL = TGs/5) [12]; Low density lipoprotein was calculated using the following formula (LDL-c mg/ dl = Non HDL-c - TG\*20%; Non HDL-c = TC - HDL-c) [12]; Direct Bilirubin (REF 80553) and Total Bilirubin (REF 80443). total and direct bilirubin purchased from (BIOLABO SA, 02160, Maizy, France, orders made at "sales@biolabofr") and following manufacturer instructions.

Parameter of glucose tolerance include; Insulin detected using ELISA Kit, Rat (Cat. Number ERINS) purchased from Thermo Fischer scientific 81 Wyman Street Waltham, MA USA 02451; blood glucose (GL F400 CH) purchased from (chema Diagnostica 60030 Monsano (AN)- ITALY-EU). ELIZA kits for detection of Rat Tumor necrosis factor-alpha (TNF-α: K0331196); Rat Interleukin-6 (IL-6: K0331229); Rat Interleukin-10 (IL-10: K0332134) purchased from Koma Biotech INC, 19F, IS BIZ Tower, Sunyudo Station 1cha, Yangpyeong-dong 5 ga 1-1, Yeongdeungpo-gu, Seoul 150-105, South Korea). All biochemical analysis done following the manufacture instructions and using Auto Biochemistry analyzer (Robonite Prietest-touch-India).

### **II.5 Collection of histological specimens**

Liver samples were taken for histological evaluation. Slices from this organ were fixed in 10% neutral buffered formalin for 24 h. The slices were embedded in paraffin, sectioned at 5 µm After automated dehydration through a graded series of alcohol. Then, sections were stained with hematoxylin and eosin, before being evaluated using a Leitz light research microscope (Leitz Wetzlar, Germany). Blind analysis of morphological changes was performed.

## **II.6 Statistical Analysis**

GraphPad Prism 5 (GraphPad Software Inc., La Jolla, CA, USA) was used for data analysis. Data were presented as mean  $\pm$ SD. Data were compared among the two groups using unpaired and paired two tailed t-test as appropriate. Data were compared among the three groups using One Way ANOVA with Bonferroni Multiple Comparison as posthoc test. A (*P*) value of less than 0.05 was considered to represent a statistically significant difference.

## **III. Results**

### **III.1 Effect of olanzapine and co-administration of vitamin D and olanzapine on total body weight and waist circumference:**

We found significant increase in the final total body weight (TBW) compared to the original body weight in each group. Neither original nor final weight were significantly different between olanzapine (O), olanzapine plus vitamin D (O+D), and control (C) groups. Insignificant difference in the percentage change (%) of body weight between the three groups (Table 1 and Fig. 1; n=6 in each group). Significant increase in final waist circumference (WTC) at the end of the study compared to original ones at the beginning of the study in the control group. Insignificant difference in final WTC in O group and O+D group compared to their original WTC. Insignificant difference in percentage change in waist circumference between the three groups. Original WTC were significantly higher in the O group compared to both C and O+D groups and in the O+D compared to C group (Table 1 and Fig.1; n=6 in each group).

### **III.2 Effect of olanzapine and co-administration of vitamin D and olanzapine on plasma lipid profile:**

Olanzapine administration for five weeks caused highly significant rise in plasma triglycerides (TGs), very low density lipoproteins (VLDL), total cholesterol (TC), and low density lipoproteins (LDL-c) compared to control group. Co administration of vitamin D caused highly significant decrease in LDL-c in O+D group compared to O group and rise in HDL/LDL ratio. However, it caused further significant rise in TGs, VLDL, and TC levels compared to both O and C groups. Insignificant difference in high-density lipoproteins (HDL-c) between the three groups and in LDL-c in O+D compared to C group (Fig. 2A & B; n=6 in each group).

### **III.3 Effect of olanzapine and co-administration of vitamin D and olanzapine on plasma total bilirubin, direct bilirubin, total protein and albumin levels**

Olanzapine administration caused highly significant rise in plasma total bilirubin and significant decrease in total protein as well as albumin compared to control group. Co administration of vitamin D caused further significant rise in total bilirubin and significant decrease in total protein and albumin compared to both O and C groups. Insignificant difference in direct bilirubin between the three groups were found (Fig. 3; n=6 in each group).

### **III.4 Effect of olanzapine and co-administration of vitamin D and olanzapine on plasma levels of liver enzymes**

Highly significant rise in plasma glutamate-pyruvate transaminase (ALT), glutamate-oxaloacetate transaminase (AST), alkaline phosphatase (ALP), and gamma glutamyl transaminase (GGT) in O group compared to C group. Co administration of vitamin D caused further highly significant rise in ALT, AST, and GGT compared to both O and C groups. Significant rise in ALP in O+D group compared to C group was found. Insignificant difference in ALP in O+D group compared to O group (Fig. 4; n=6 in each group).

### **III.5 Effect of olanzapine and co-administration of vitamin D and olanzapine on blood glucose and insulin levels**

Significant rise in blood glucose and highly significant decrease in insulin levels in O group compared to C group. Co administration of vitamin D caused further significant rise blood sugar in O+D group compared to both O and C groups. Insignificant difference in blood insulin level in O+D group compared to O group. Significant decrease in blood insulin level in O+D group compared to C group (Fig. 5; n=6 in each group).

### **III.6 Effect of olanzapine and co-administration of vitamin D and olanzapine on plasma levels pro-inflammatory cytokines**

Highly significant rise in plasma interleukin 6 (IL-6), interleukin 10 (IL-10), and tumor necrosis factor alpha (TNF- $\alpha$ ) levels in O group compared to C group. Co administration of vitamin D caused further significant rise blood sugar in O+D group compared to both O and C groups. (Fig. 6; n=6 in each group).

### **III.7 Effect of olanzapine and co-administration of olanzapine and vitamin D on liver histology.**

Liver tissue of control group (Fig. 7 A) showed normal size of blood sinusoids (arrow) and normal appearance of hepatocytes (arrowhead). Liver tissue from olanzapine group (Fig. 7 B) showed dilated blood sinusoids with inflammatory cell infiltration (arrow), vacuolated cytoplasm of hepatocytes (arrowhead), shrunken hepatocytes with pyknotic nuclei (asterisk). C: Liver tissue of (O+D) group (Fig. 7 C) showed vacuolated cytoplasm of hepatocytes (arrowhead), apoptotic cells are less frequently seen (asterisk), and less inflammatory cells infiltration.

#### **IV. Discussion**

Metabolic side effects as increased food intake, weight gain, disturbed lipid profile, and hepatic steatosis is common side effects to administration of atypical antipsychotic [13]. Current study showed significant rise in VLDL, TGs, TC, and LDL-c with administration of 5mg/kg olanzapine daily for five weeks. However, insignificant difference in weight gain and abdominal fat in olanzapine group compared to control group were found. In line with us, He and his group reported that olanzapine-induced hyperphagia and weight gain is time dependent as it occurred during the first week of treatment and were absent when treatment is prolonged to two or five weeks [14]. They added that olanzapine effect in the first week was due to phosphorylation of AMP-activated protein kinase and phospho-acetyl-coenzyme A carboxylase in dorsal vagal nucleus that was absent after prolonged treatment. Fernø and his group reported that although, olanzapine at 200mg/kg or higher didn't cause any weight gain in female rats, it caused significant rise in TC and activated hepatic expression of lipogenic enzymes [15]. In contrast to us, several previous studies reported significant linear rise in body mass index with the rise in plasma lipids and fasting glucose with olanzapine treatment of patients with newly diagnosed psychosis for 16 weeks [16]. This discrepancy could be explained based on species difference as they were clinical studies done on humans and not rats.

We found that co-administration of active vitamin D3 at 125 mcg/ Kg twice weekly for 5 weeks caused significant decrease in LDL-c and rise in HDL/LDL ratio compared to olanzapine group. In line with us, Jafari et al. reported significant decrease in LDL-c with vit.D3 supplementation in patients with type II diabetes in meta-analysis including seventeen studies [17]. Unfortunately, administration of vit.D3 caused further significant rise in VLDL, TGs, and TC and insignificant difference in weight gain compared to both olanzapine group and control group. Neither olanzapine nor olanzapine and vitamin D administration caused significant difference in HDL-c plasma level. In support of this result, Fernandez-Egea et al reported significant rise in TGs, TC, LDL-c and insignificant change in HDL-c with olanzapine administration for 16 weeks [16].

We investigated the effect of olanzapine alone and co-administration of olanzapine and vitamin D on plasma levels of total bilirubin, direct bilirubin, total protein, albumin, and liver enzymes; ALT, AST, ALP and GGT. The results of this study showed highly significant rise in all the previous parameters of liver function with vitamin D administration compared to both olanzapine and control groups. Han and his colleagues administered 1- 25 Di-OH choliciferol at different dose regimen (1, 5, 10 mcg twice weekly for 12 weeks) to rats [18]. They found that treatment with low dose of vitamin D decreased free fatty acids, TGs and decreased the number of apoptotic cells in the liver, however, higher doses caused the reverse. They suggested that administration of higher dose of active vitamin D3 has adverse effects in rat model of choline-deficient diet-induced hepatic steatosis.

Olanzapine administration causes metabolic complication leading to hyperglycemia and diabetes [5], [19]. Other studies suggested that the use of calcitriol improves glucose tolerance, visceral fat accumulation and function of vascular endothelium [20-22]. Our results revealed that co-administration of vitamin D didn't protect against glucose intolerance induced by olanzapine. Instead, it caused aggravation of olanzapine induced hyperglycemia and significantly decreased insulin level compared to controls. In support of our results, many clinical studies reported that vitamin D didn't correct abnormal glucose tolerance [23].

In fact, Neilsen and his group found a positive correlation between administration of 25-OH choliciferol at (255 nmol/L) that is far below the dose that adversely affect glucose measures or health (500 nmol/L) [24]. Moreover, Heaney reported that intake of very high doses of vitamin D might have toxic adverse effects on humans [25]. Baynes et al reported inverse correlation between blood insulin level and the concentration of 25 hydroxy vitamin D3 in 142 elderly Dutchmen measured during oral glucose tolerance test [26]. The adverse effects of vitamin D could be explained by upregulation of 24 hydroxylase induced by high intake of vitamin D that inactivate vitamin D to 1, 24, 25-OH-D3.[27] High intake of marine diet which is known to be rich in vitamin D may be source of excess environmental contaminants which might mediate the adverse effects of vitamin D on glucose tolerance [24].

Vitamin D deficiency is associated with increased susceptibility to infection [28]. Previous studies showed correlation between body status of vitamin D as well as olanzapine administration and immune function. This study demonstrated significant rise in IL-6, IL-10 and TNF-alpha in olanzapine group compared to controls and further significant rise in olanzapine plus vitamin D group compared to both control and olanzapine group. In line with us, previous clinical studies reported rise in IL-6 and TNF-alpha with

administration of high dose of vitamin D whether in healthy children or adult psychotic patients with olanzapine treatment [29, 30]. In addition, several studies demonstrated significant rise in IL-10 with or without rise of TNF-alpha in patients with vit.D3 administration. [31-33] Liu et al found significant rise in IL-10 and IL-4 after administration of active vit.D3 for 6 weeks in rat model of autoimmune thyroiditis [9].

Previous studies showed correlation between TNF-alpha and interleukin-10 that is important to maintain immune homeostasis. The rise of TNF-alpha in case of severe inflammation caused compensatory rise in the protective cytokine IL-10 that inhibits the production of other inflammatory mediators [34]. This study showed that olanzapine caused histopathological damage in liver cells with dilated blood sinusoids, inflammatory cell infiltration, vacuolated cytoplasm of hepatocytes, and shrunken apoptotic hepatocytes. Several previous studies showed the damaging effect of olanzapine and other AAD on liver cells. Soliman et al. reported that olanzapine (0.5mg/Kg/day) treatment for 14 weeks caused marked steatosis of hepatocytes in rats with large fatty droplets, vacuolated cytoplasm, apoptotic nuclei, enlarged mitochondria, sinusoidal neutrophil infiltration, and deposition of collagen around the hepatic sinusoids [1]. Although, co-administration of high dose vitamin D caused worsening of serological parameters of liver function, it caused less damage of liver histology. The present study showed milder damage of liver cells in O+D group compared to O group with less vacuolated cytoplasm of the hepatocytes, decreased apoptotic cells and milder sinusoidal dilatation. Taken together, we may speculate that the ability of vit.D3 to significantly elevate the anti-inflammatory cytokines; IL-6 and IL-10 might be the underlying factor that provide mild resistance of hepatocytes to apoptosis and damage.

## V. Conclusion

This study provide further evidence for the metabolic disorders caused by olanzapine that was independent of weight gain. Moreover, we showed that co- administration of vitamin D was not protective against olanzapine induced hepatic and metabolic disorders. As it caused further elevation of plasma TNF-alpha, liver enzymes, plasma TGS, VLDL, TC and glucose as well as reduction in insulin. On the other hand, it produced significant elevation of HDL/LDL, anti-inflammatory cytokines (IL-6 & IL-10) and mild improvement of hepatic architecture induced by olanzapine. We suggest that we should be careful concerning intake of high doses of vitamin D particularly in persons with normal plasma level of this vitamin and treated with olanzapine.

## Conflict Of Interest

No conflict of interest.

## Acknowledgment:

The Authors would like to thank Dr. Soha. A. abdelwaham Lecturer, Department of Histology, Minia University, Egypt, visitor Faculty at Department of Basic Medical sciences, Deraya University for her great help in taking and commenting on the histology images.

## References

- [1]. H.M.Soliman, H.M.Wagih, S.A.Algaidi, A.H.Hafiz. Histological evaluation of the role of atypical antipsychotic drugs in inducing non-alcoholic fatty liver disease in adult male albino rats (light and electron microscopis study). *Folia Biologica (Praha)*. 59, 2013, 173-180.
- [2]. D.J.Pousy, Ka.Stigler, C.A.Erickson,C.J.McDougle. Antipsychotics in the treatment of autism. *J. Clin. Invest.* 118, 2008, 6-14.
- [3]. A.F.Naomi, M.G.Tim, S. Thanusha. A review of antipsychotics in the treatment of obsessive compulsory disorder. *Focus* 5, 2007, 354-360.
- [4]. H.Y.Meltzer. Update on typical and atypical antipsychotic drugs. *Annu Rev Med.* 64, 2013, 393-406.
- [5]. P.M. Haddad, S.G.Sharma. Adverse effects of atypical antipsychotics. *CNS drugs* 21(11), 2007, 911.
- [6]. M.G. Melka, N.Rajakumar, R.O'Reilly, S.M.Singh. Olanzapine-induced DNA methylation in the hippocampus and cerebellum in genes mapped to human 22q11 and implicated in schizophrenia. *Psychiatr Genet. Apr*; 25(2), 2015, 88-94.
- [7]. R.Dang, P.Jiang,H.Cai,H.Li,R.Guo,Y.Wu,L.Zhang,WZhu,X.He,Y.Liu,P.Xu. Vitamin D deficiency exacerbates atypical antipsychotic-induced metabolic side effects in rats: Involvement of the INSIG/SREBP pathway. *EurNeuropsychopharmacol.* May9. pii: S0924-977X(15), 2015, 00148-0.
- [8]. O.Erbaş, V.Solmaz,D.Aksoy, A.Yavaşoğlu, M.Saçcan, D.Taşkıran. Cholecalciferol (vitamin D 3) improves cognitive dysfunction and reduces inflammation in a rat fatty liver model of metabolic syndrome. *Life Sci.* May17; 103(2), 2014, 68-72.
- [9]. X.J.Liu, B.W. Wang, C. Zhang, M.Z. Xia, Y.H.Chen, C.Q. Hu, et al. Vitamin D deficiency attenuates high-fat diet-induced hyperinsulinemia and hepatic lipid accumulation in male mice. *Endocrinology.* Jun; 156(6), 2015, 2103-13.
- [10]. A.A.Irving, L.A.Plum, W.J.Blaser, M.R.Ford, C.Weng, L.Clipson, H.F.DeLuca, W.F.Dove.Cholecalciferol or 25-hydroxycholecalciferol neither prevents nor treats adenomas in a rat model of familial colon cancer. *J Nutr.* Feb;145(2), 2015, 291-8.
- [11]. M.Gerbaix, L.Metz, E.Ringot, D.Courteix. Visceral fat mass determination in rodent: validation of dual-energy x-ray absorptiometry and anthropometric techniques in fat and lean rats. *Lipids in Health and Disease.* Dec 9; 9, 2010, 140.
- [12]. A.J.Tremblay, H.Morrisette, J.M.Gagne, J.Bergeron, C.Gagne, P.Couture. (2004) Validation of the Friedewald formula for the determination of low-density lipoprotein cholesterol compared with beta-quantification in a large population. *ClinBiochem.* ;37(9):785-790.

[13]. R.Dang, P.Jiang, H.Cai, H.Li, R.Guo, Y.Wu, L.Zhang, W.Zhu, X.He, Y. Liu, P.Xu. Vitamin D deficiency exacerbates atypical antipsychotic-induced metabolic side effects in rats: Involvement of the INSIG/SREBP pathway. *Eur Neuropsychopharmacol.* May 9. pii: S0924-977X(15), 2015, 00148-0.

[14]. M.He, Q.Zhang, C.Deng, H.Wang, X.F.Huang. Olanzapine-activated AMPK signaling in the dorsal vagal complex is attenuated by histamine H1 receptor agonist in female rats. *Endocrinology.* Dec;155(12), 2014,4895-904.

[15]. J.Fernø, K.M.Erslund, I.H. Duus, I. González-García, K.O.Fossan, R.K. Berge, V.M.Steen, S.Skrede. Olanzapine depot exposure in male rats: Dose-dependent lipogenic effects without concomitant weight gain. *Eur Neuropsychopharmacol.* Jun;25(6), 2015,923-32.

[16]. E.Fernandez-Egea, B.Miller, C.Garcia-Rizo, M.Bernardo, B.Kirkpatrick. Metabolic effects of olanzapine in patients with newly diagnosed psychosis. *J Clin Psychopharmacol.* Apr;31(2), 2011, 154-9.

[17]. T. Jafari, A.A. Fallah, A. Barani. Effects of vitamin D on serum lipid profile in patients with type 2 diabetes: A meta-analysis of randomized controlled trials. *Clin Nutr.* 2016 Mar 15. pii: S0261-5614(16)00090-X. doi:10.1016/j.clnu.2016.03.001.

[18]. H.Han, M.Cui, X.You, M. Chen, X.Piao, G.Jin. A role of 1,25(OH)2D3 supplementation in rats with nonalcoholic steatohepatitis induced by choline-deficient diet. *Nutr Metab Cardiovasc Dis.* Jun;25(6), 2015, 556-61.

[19]. C.J.Lynch, Y.Xu, A.Hajnal, A.C.Salzberg, Y.I.Kawasawa. RNA sequencing reveals a slow to fast muscle fiber type transition after olanzapine infusion in rats. *PLoS One.* Apr20; 10(4), 2015, e0123966.

[20]. C.L.Chou, C.Y.Pang, T.J.Lee, T.C.Fang. Beneficial effects of calcitriol on hypertension, glucose intolerance, impairment of endothelium-dependent vascular relaxation, and visceral adiposity in fructose-fed hypertensive rats. *PLoS One.* Mar16;10(3), 2015, e0119843.

[21]. C.Ning, L.Liu, G.Lv, Y.Yang, Y.Zhang, R.Yu, Y.Wang, J.Zhu. Lipid metabolism and inflammation modulated by Vitamin D in liver of diabetic rats. *Lipids Health Dis.* Apr 18;14, 2015, 31.

[22]. A.G. Pittas, M.Chung, T.Trikalinos, J Mitri, M Brendel, K Patel, et al. Systematic review: Vitamin D and cardiometabolic outcomes. *Ann Intern Med.* 152, 2010, 307–14.

[23]. B.J.Boucher, N.Mannan, K.Noonan, C.N.Hales, S.J.W.Evans. Glucose intolerance and impairment of insulin secretion in relation to vitamin D deficiency in East London Asians. *Diabetologia.* Oct;38(10), 1995, 1239-1245.

[24]. N.O.Nielsen, P.Bjerregaard, P.F.Rønn, H.Friis, S.Andersen, M.Melbye, et al. Associations between Vitamin D Status and Type 2 Diabetes Measures among Inuit in Greenland May Be Affected by Other Factors. *PLoS One.* Apr 13;11(4), 2016, e0152763.

[25]. R.P.Heaney. Vitamin D: criteria for safety and efficacy. *Nutr Rev.* 66 (suppl 2), 2008, 178–181.

[26]. K.C.R.Baynes, B.J.Boucher, E.J.M.Feskens. Vitamin D, glucose tolerance and insulinaemia in elderly men. *Diabetologia.* 40(3), 1997, 344.

[27]. G.J.Miller, G.E.Stableton, T.E.Hedlund, K.A.Moffatt. Vitamin D receptor expression, 24-hydroxylase activity, and inhibition of growth by 1 $\alpha$ ,25-dihydroxyvitamin D3 in seven human prostatic carcinoma cell lines. *Clin Cancer Res.* 1995; 1: 997–1003. PMID: 9816072.

[28]. C.Aranow. Vitamin D and the immune System. *J Investig Med.* Aug. 59(6), 2011, 881–886.

[29]. N.Brett, S.Agellon, C.Vanstone, and H.Weiler. Vitamin D status positively associates with interleukin-6 and tumour necrosis factor alpha in healthy young children. *The FASEB J.* Apr;28(1), 2014, Supplement 40.8.

[30]. M.Kluge, A.Schuld, A.Schacht, H.Himmerich, M.A.Dalal, P.M.Wehmeier, et al. Effects of clozapine and olanzapine on cytokine systems are closely linked to weight gain and drug-induced fever. *Psychoneuroendocrinol.* Jan;34(1), 2009, 118-28.

[31]. F.Ashtari, N.Toghianifar, S.H.Zarkesh-Esfahani, M.Mansourian. Short-term effect of high-dose vitamin D on the level of interleukin 10 in patients with multiple sclerosis: a randomized, double-blind, placebo-controlled clinical trial. *Neuroimmunomodulation.* 22(6), 2015, 400-4.

[32]. G.Heine, U.Niesner, H.D.Chang, A.Steinmeyer, U.Zügel, T.Zuberbier, A.Radbruch, M.Worm. 1,25-dihydroxyvitamin D(3) promotes IL-10 production in human B cells. *Eur J Immunol.* Aug;38(8), 2008,2210-8.

[33]. S.S.Schleithoff, A.Zittermann, G.Tenderich, H.K.Berthold, P.Stehle, R.Koerfer. Vitamin D supplementation improves cytokine profiles in patients with congestive heart failure: a double-blind, randomized, placebo-controlled trial. *Am J Clin Nutr.* Apr;83(4), 2006, 754-9.

[34]. G.V.Shmarina, A.L. Pukhalsky, S.N.Kokarovtseva, D.A.Pukhalskaya, L.A. Shabalova, N.I.Kapranov, N.J.Kashirskaja. Tumour necrosis factor-alpha/interleukin-10 balance in normal and cystic fibrosis children. *Mediators Inflamm.* Aug.;10(4), 2001, 191–197.

VII. Tables

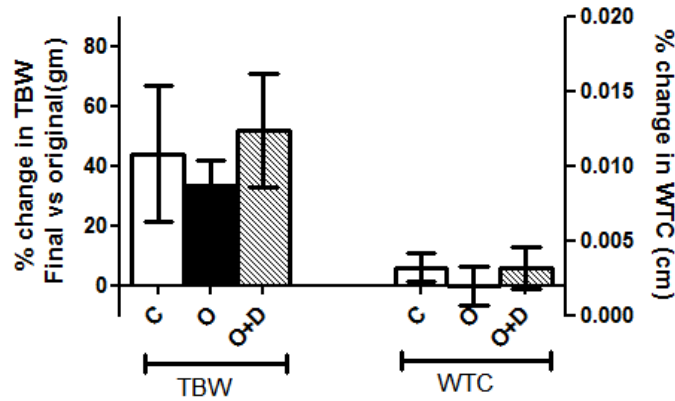
Table 1. Changes in total body weight and waist circumference with olanzapine or olanzapine and vitamin D administration.

TBW	C <sub>o</sub>	C <sub>f</sub>	% TBW	O <sub>o</sub>	O <sub>f</sub>	% TBW	O+D <sub>o</sub>	O+D <sub>f</sub>	% TBW
Mean	123	171**	44	119	159***	33	92	143**	52
Std. Dev	39	37	23	13	19	8.3	12	12	19
Std. Err.	16	15	9.3	5.4	7.7	3.4	4.8	5.5	8.5
Min.	75	129	24	110	139	26	75	131	36
Max.	165	208	74	145	188	50	105	158	82
WTC	C <sub>o</sub>	C <sub>f</sub>	% WTC	O <sub>o</sub>	O <sub>f</sub>	% WTC	O+D <sub>o</sub>	O+D <sub>f</sub>	% WTC
Mean	11	12*	5.9	13***	13	-0.24	12#	13	5.8
Std. Dev	0.21	0.45	4.7	0.45	0.93	6.4	0.32	0.91	6.9
Std. Err.	0.084	0.18	1.9	0.18	0.38	2.6	0.13	0.41	3.1
Min.	11	12	0	13	12	-7.7	12	12	0
Max.	12	13	11	14	15	7.4	13	14	17

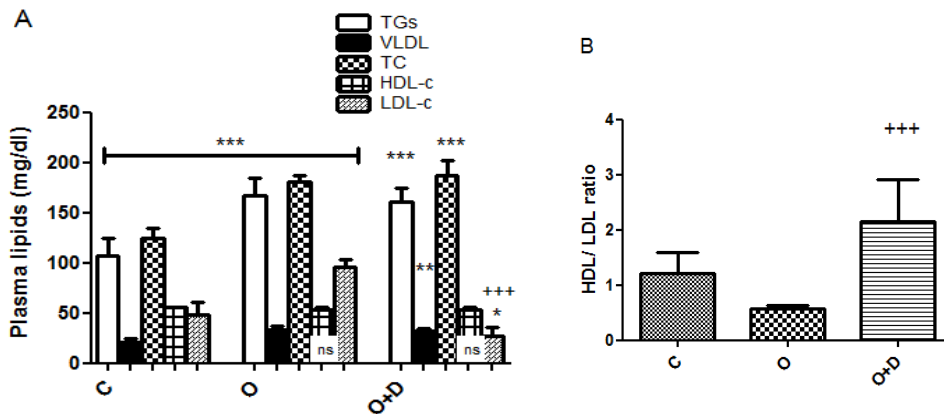
Mean TBW: total body weight; mean WTC: waist circumference; C: control group; O: olanzapine group; O+D: olanzapine+ vitamin D group; gm: grams; f: final; o: original; % change = (TBW<sub>f</sub> – TBW<sub>o</sub>)/TBW<sub>o</sub>\*100; (\*) significance level of final TBW or WTC vs original TBW or WTC in the same group; (+) significance of O

group vs both C and O+D groups; (#) significance of O+D vs C group; Standard Deviation (Std. Dev); Standard Error: Std. Err.; Min. : minimum; Max. : maximum (\*P < 0.05; \*\*P < 0.01; \*\*\*P < 0.005; n= 6 in each group).

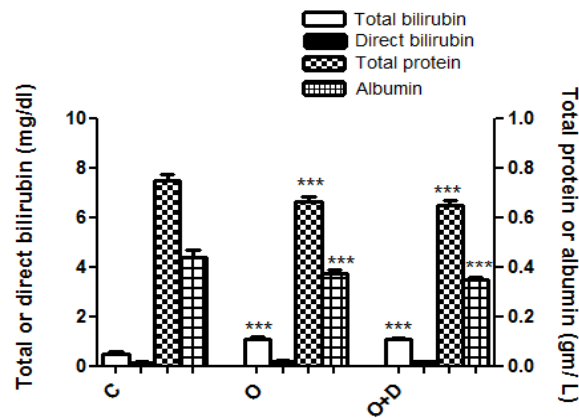
VII. Figures



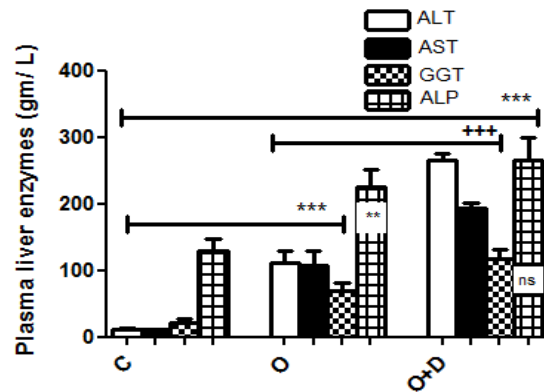
**Fig 1:** Changes in total body weight and waist circumference with olanzapine or olanzapine and vitamin D administration. Mean %TBW: total body weight ± Standard Deviation (STDEV); mean %WTC: waist circumference ± STDEV; C: control group; O: olanzapine group; O+D: olanzapine+ vitamin D group; gm: grams; cm(centimeters); f: final; o: original; % change =  $(TBW_f - TBW_o)/TBW_o * 100$ ; % change in WTC =  $(WTC_f - WTC_o)/WTC_o * 100$ ; (n= 6 in each group).



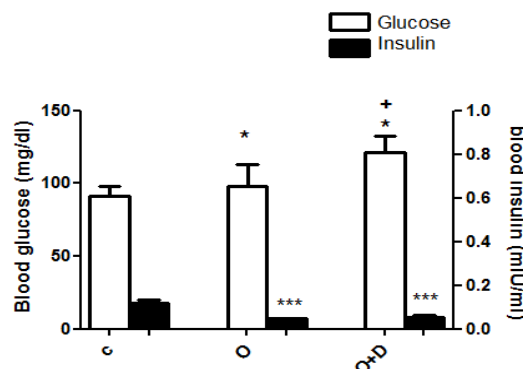
**Fig 2:** A: parameter of lipid profile; B: HDL/LDL ratio; triglycerides (TGs); very low density lipoproteins (VLDL); total cholesterol (TC), high density lipoproteins (HDL-c); low density lipoproteins (LDL-c); C: control group; O: olanzapine group; O+D: olanzapine+ vitamin D group; mg/dl: milligrams/ deciliter; mIU/ ml (milli Unit/ milliliter); (\*) or (ns) significance level of O or O+D group vs control; ; (+) significance level of O+D group compared to O group; (ns P > 0.05; \*\*\*P < 0.005; +++P < 0.005; n= 6 in each group).



**Fig 3:** Changes in blood total bilirubin, direct bilirubin, total protein and albumin levels with olanzapine or olanzapine and vitamin D administration. C: control group; O: olanzapine group; O+D: olanzapine+ vitamin D group; mg/dl: milligrams/ deciliter; gm/L: grams/ Liter; (\*) significance level of O or O+D group vs control (\*\* $P < 0.005$ ;  $n = 6$  in each group).

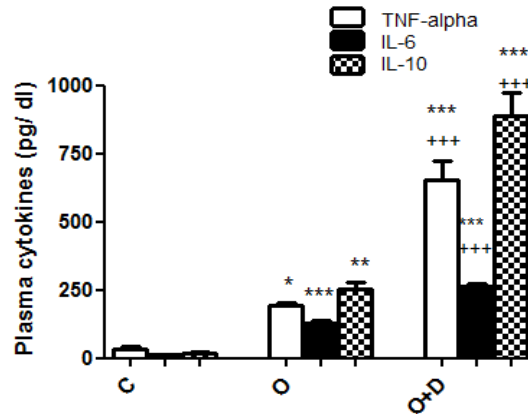


**Fig 4.** Changes in plasma levels of liver enzymes with olanzapine or olanzapine and vitamin D administration. glutamate/oxaloacetate transaminase (ALT); glutamate/pyruvate transaminase (AST); gamma glutamyl transaminase (GGT); and alkaline phosphatase (ALP). C: control group; O: olanzapine group; O+D: olanzapine+ vitamin D group; gm/L: grams/ Liter; (\*) significance level of O or O+D group vs control group; (+) significance level of O vs O+D group (\*\* $P < 0.01$  O vs C groups; \*\*\* $P < 0.005$ ; +++ $P < 0.005$ ; ns  $P > 0.05$  in O+D vs O groups;  $n = 6$  in each group).

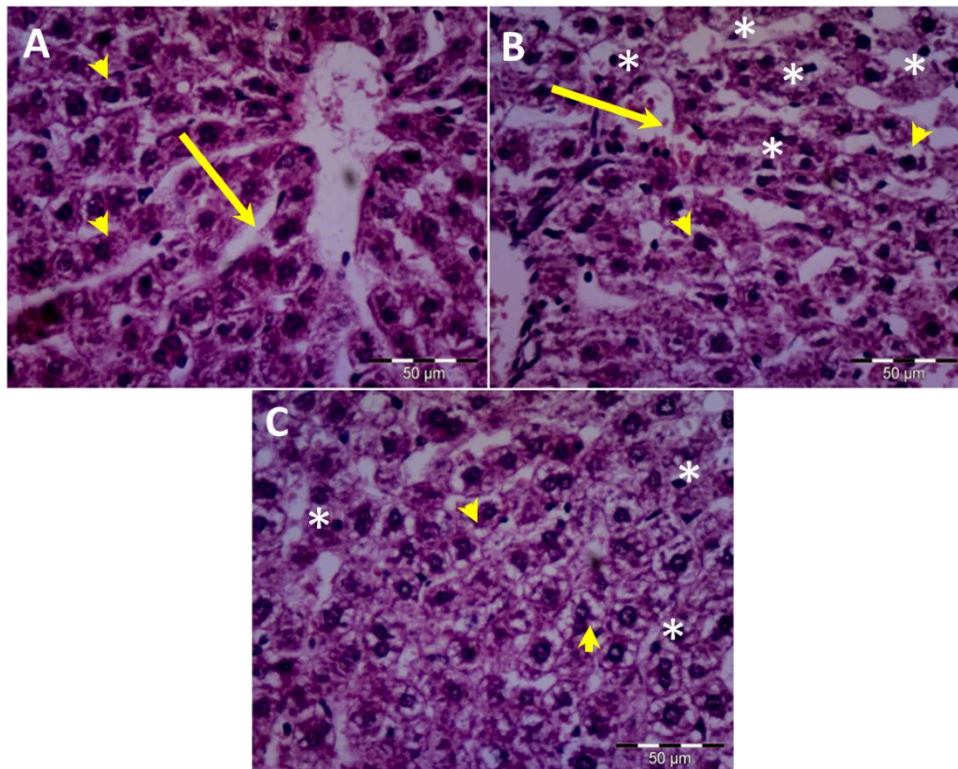


**Fig 5.** Changes in blood glucose and blood insulin level with olanzapine or olanzapine and vitamin D administration. C: control group; O: olanzapine group; O+D: olanzapine+ vitamin D group; mg/dl: milligrams/ deciliter; mIU/ ml (milli Unit/ milliliter); (\*) significance level of O or O+D group vs control; (+) significance level of O+D group vs O group (\* $P < 0.05$ ; \*\*\* $P < 0.005$ ; + $P < 0.05$ ;  $n = 6$  in each group).





**Fig 6. Changes in blood level of pro-inflammatory cytokines with olanzapine or olanzapine and vitamin D administration.** Interleukin-6 (IL-6); interleukin-10 (IL-10); tumor necrosis factor alpha (TNF- $\alpha$ ); C: control group; O: olanzapine group; O+D: olanzapine+ vitamin D group; pg/dl: picograms/ deciliter; (\*) significance level of O or O+D group vs control; (+) significance level of O+D group vs O group (\*P < 0.05; \*\*P < 0.01; \*\*\*P < 0.005; +++P < 0.005; n= 6 in each group).



**Fig 7:**Photomicrograph of rat liver tissue of olanzapine or olanzapine and vitamin D treated rats. A: liver tissue of control group showing normal size of blood sinusoids (arrow) and normal appearance of hepatocytes (arrowhead); B: liver tissue from olanzapine group showing dilated blood sinusoids with inflammatory cell infiltration (arrow), vacuolated cytoplasm of hepatocytes (arrowhead), shrunken hepatocytes with pyknotic nuclei (asterisk); C: Liver tissue of (O+D) group showing vacuolated cytoplasm of hepatocytes (arrowhead), apoptotic cells are less frequently seen (asterisk), and no inflammatory cells could be detected. (H&E; Magnification X 400).